

Case of the Month—November 2006

FDG-PET for Metastatic Pancreatic Cancer

History

In 2004, a 54-year-old female was diagnosed with adenocarcinoma of the pancreas, Stage III, T3N1MO status post-Whipple procedure. In early 2006, the patient presented with rising CA19-9. A body CT scan failed to detect any metastasis. FDG-PET was then performed.

Findings

Upon performing a PET scan, two adjacent foci of abnormal increased FDG uptake were observed in the left common iliac region that are more prominent on the delayed study (Figure 1). These are consistent with metastases. No significant focal hypermetabolism was seen in the pancreatic bed or liver.

Follow Up

An MRI scan taken after the PET study confirmed abnormal left iliac lymph nodes. The patient then received 5 cycles of chemotherapy (gemcitabine and bevacizumab). A restaging non-contrast CT scan showed no new lesions. The follow-up FDG-PET revealed a new focus of intense uptake in the left hepatic lobe (Figure 2).

Discussion

The value of FDG-PET for pancreatic cancer is still under

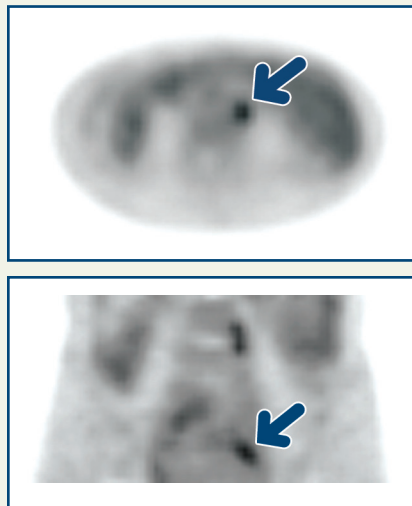


Figure 1

investigation. One study found that “FDG-PET reliably detected local recurrences, whereas CT/MRI was more sensitive for the detection of hepatic metastases. Furthermore, FDG-PET proved to be advantageous for the detection of non-locoregional and extra-abdominal recurrences¹.” Another study found that “PET had a similar accuracy to that of CT for imaging pancreatic cancer but it did not provide any additional information in patients with equivocal CT findings and currently would seem of little benefit for the staging of pancreatic cancer².” In this case, we found that FDG-PET was useful for detecting recurrent pancreatic liver metastasis.

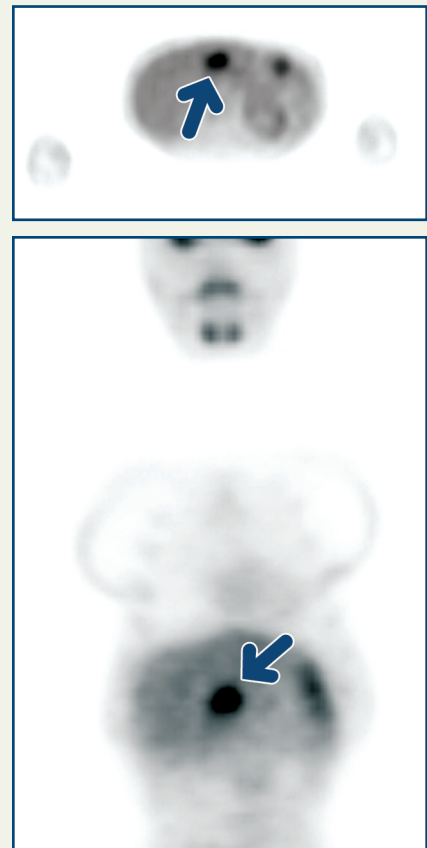


Figure 2

(1) Ruf, J., et al. “Detection of recurrent pancreatic cancer: comparison of FDG-PET with CT/MRI.” *Pancreatology* 2005, 5(2-3): 266-72. Epub 2005, April 22.

(2) Lytras, D., et al. “Positron emission tomography does not add to computed tomography for the diagnosis and staging of pancreatic cancer.” *Digital Surgery* 2005, 22 (1-2): 55-61; discussion 62. Epub 2005, April 14.

Copyright 2006 New England PET Imaging System

www.nepetimaging.com

NEPET at Holy Family Hospital
 70 East Street
 Methuen, MA 01844
 (978) 689-4738

NEPET of Greater Lowell
 Lowell General Hospital Cancer Center
 295 Varnum Avenue
 Lowell, MA 01854
 (978) 458-9872

NEPET at Elliot Hospital
 One Elliot Way
 Manchester, NH 03103
 (603) 663-2370

Massachusetts Mobile PET, P.C.
 at Anna Jaques Hospital
 25 Highland Avenue
 Newburyport, MA 01950
 (888) 560-4738

Massachusetts Mobile PET, P.C.
 at Merrimack Valley Hospital
 140 Lincoln Avenue
 Haverhill, MA 01830
 (888) 560-4738