

Case of the Month—December 2006

PET/CT for Detecting Recurrent Lymphoma

History

This case involves a 30-year-old female with a history of Hodgkin's lymphoma. She had completed a course of chemotherapy and had received a bone marrow transplant. Her regular follow-up CT scan showed that she had a stable small cervical lymph node. A PET/CT scan was performed to rule out recurrence of the lymphoma.

Findings

Three foci of abnormal uptake were identified on the PET scan, with two seen in the neck. These correlate with a 10mm left cervical node just anterior to the sternocleidomastoid muscle and an 8mm node in the right neck on PET/CT fusion image (Figures 1 and 2). In addition, there was a focus of hypermetabolism correlating with a 5mm left axillary node on the PET/CT fusion image (Figure 3).

Discussion

The advantages of PET/CT scan versus a scan by PET alone include: shorter scan time allowing for greater patient comfort, reduced patient motion providing for greater image accuracy, the ability to pinpoint the exact location of abnormal metabolic focus, and the scan clarity allows for greater confidence in the results by the interpreting physician. In the above case, for example, PET alone showed all the abnormal metabolic foci but was unable to indicate which lymph node was involved. With the PET/CT fusion study, we can confidently tell the referring physician the exact location of recurrence.

Copyright 2006 New England PET Imaging System

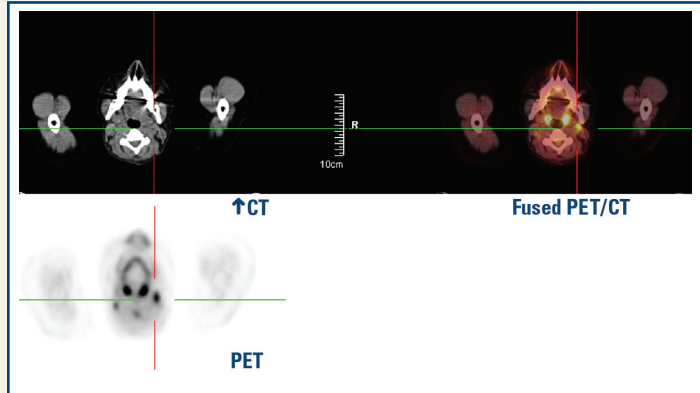


Figure 1

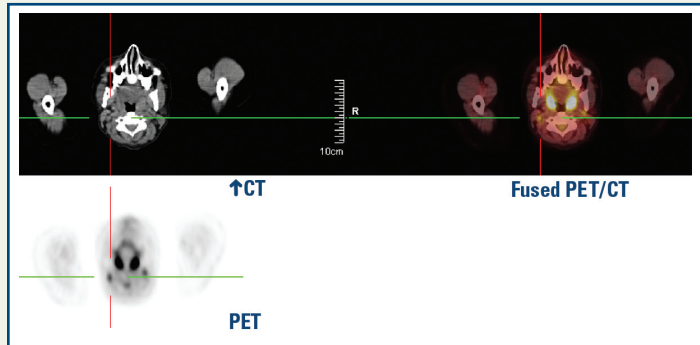


Figure 2

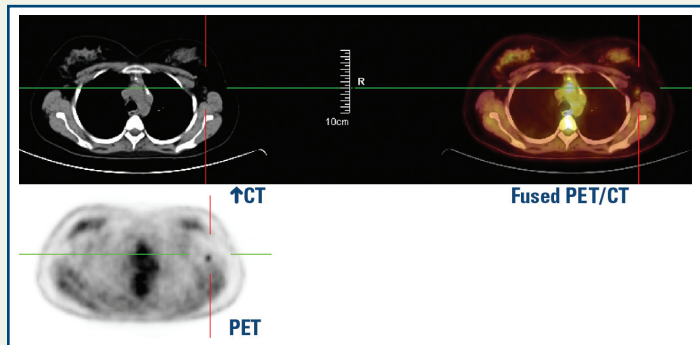


Figure 3

www.nepetimaging.com

NEPET at Holy Family Hospital
 70 East Street
 Methuen, MA 01844
 (978) 689-4738

NEPET of Greater Lowell
 Lowell General Hospital Cancer Center
 295 Varnum Avenue
 Lowell, MA 01854
 (978) 458-9872

NEPET at Elliot Hospital
 One Elliot Way
 Manchester, NH 03103
 (603) 663-2370

Massachusetts Mobile PET, P.C.
 at Anna Jaques Hospital
 25 Highland Avenue
 Newburyport, MA 01950
 (888) 560-4738

Massachusetts Mobile PET, P.C.
 at Merrimack Valley Hospital
 140 Lincoln Avenue
 Haverhill, MA 01830
 (888) 560-4738