

Case of the Month—April 2006

FDG-PET for Restaging Lymphoma

History and PET Findings

A 46-year-old male presented with a suspicious left inguinal lymph node. Biopsy confirmed Hodgkin's disease. His initial staging study included CT and PET. Initial FDG-PET demonstrated two foci of uptake in the left inguinal region and left pelvis (Figure 1). The patient underwent 6 cycles of ABVD treatment, and a repeat PET scan revealed residual uptake in the pelvis (Figure 2). The patient was then given 30 Gy of radiation treatment. A restaging PET two months after radiation treatment showed resolution of abnormal uptake in the left pelvis. However, there was a new focus of uptake seen in the spleen which is consistent with recurrent lymphoma (Figure 3).

How Did PET Help?

In this case, FDG-PET was beneficial in guiding treatment and in the detection of recurrent lymphoma.

Discussion

FDG-PET has high diagnostic accuracy for restaging lymphoma after initial treatment. FDG-PET has shown high accuracy in the early prediction of response to chemotherapy and in the evaluation of residual masses after chemotherapy or radiation therapy. Therefore, PET is likely to play a major role in guiding treatment for lymphoma patients.

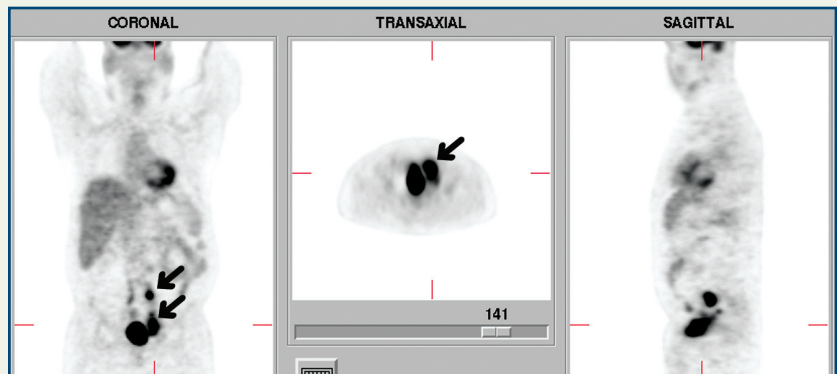


Figure 1

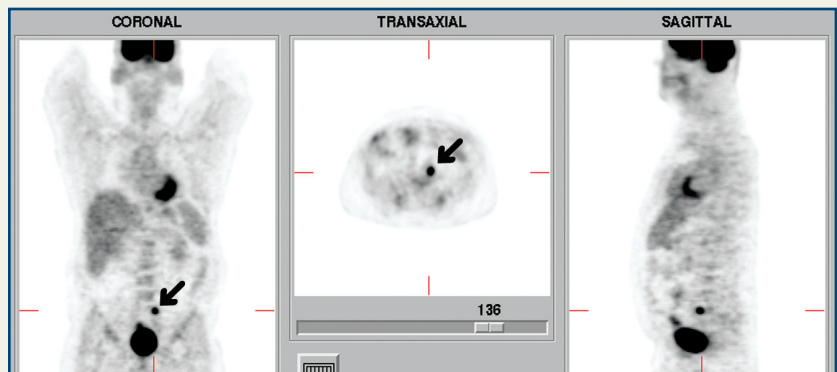


Figure 2

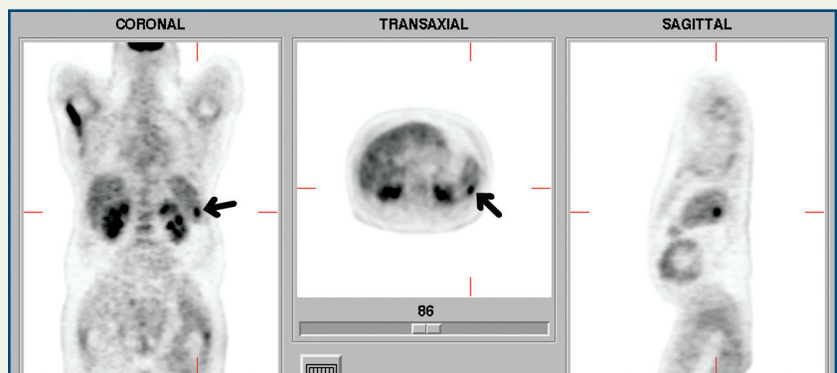


Figure 3

Copyright 2006 New England PET Imaging System

www.nepetimaging.com

NEPET at Holy Family Hospital
 70 East Street
 Methuen, MA 01844
 (978) 689-4738

NEPET of Greater Lowell
 Lowell General Hospital Cancer Center
 295 Varnum Avenue
 Lowell, MA 01854
 (978) 458-9872

NEPET at Elliot Hospital
 One Elliot Way
 Manchester, NH 03103
 (603) 663-2370

Massachusetts Mobile PET, P.C.
 at Anna Jaques Hospital
 25 Highland Avenue
 Newburyport, MA 01950
 (888) 560-4738

Massachusetts Mobile PET, P.C.
 at Merrimack Valley Hospital
 140 Lincoln Avenue
 Haverhill, MA 01830
 (888) 560-4738